Other Lymphoproliferative and Myeloproliferative Diseases

121

Cesare Massone, Harry L. Winfield and Bruce R. Smoller

Chapter Contents

Benign Lymphocytic Infiltrates 2177
Cutaneous Extramedullary Hematopoiesis 2181
Malignant Hematopoietic Infiltrates 2182

BENIGN LYMPHOCYTIC INFILTRATES

Lymphocytic Infiltrate of Jessner

Synonyms: ■ Lymphocytic infiltrate of Jessner–Kanof ■ Benign lymphocytic infiltrate of the skin ■ Jessner lymphocytic infiltrate of the skin ■ Jessner lymphocytic infiltration of the skin ■ Jessner–Kanof lymphocytic infiltration of the skin

Key features

- Erythematous papules, plaques, and less commonly nodules
- Most common on the head, neck, and back
- Dermal infiltrate of lymphocytes without epidermal involvement

History

Lymphocytic infiltrate of Jessner (LIJ) was initially described in 1953 by Jessner and Kanof[1] as circinate papules on the face, surrounding a central area of clearing.

Epidemiology

This entity occurs primarily in middle-aged adults. There is no sex predilection.

Pathogenesis

Benign lymphocytic infiltrate of the skin remains a controversial entity[2]. Several authors believe it is a variant of cutaneous lupus erythematosus (primarily LE tumidus), an opinion shared by the authors of this chapter. Rare cases of drug-induced disease (e.g. angiotensin-converting enzyme [ACE] inhibitors, glatiramer acetate, targeted immunomodulators ["biologics"]) have been described[3,4] as have familial cases[5].

Clinical features

Cutaneous lesions appear primarily on the head, neck, and back as one or several asymptomatic, erythematous papules, plaques, and less commonly nodules, with an absence of secondary epidermal changes such as scale (Fig. 121.1). Annular plaques with central clearing are commonly observed and individual lesions last several weeks to months. There are no associated systemic manifestations. Although spontaneous resolution occurs, recurrences are common.

Pathology

The epidermis is unremarkable, with little evidence of interface dermatitis. There is a superficial and deep, primarily perivascular, lymphocytic infiltrate that may surround hair follicles (Fig. 121.2). A mild increase in dermal mucin may be seen. Because some cases may be misinterpreted morphologically as a cutaneous lymphoproliferative disorder, detailed immunophenotypic studies and clinicopathological correlation are required[6]. By immunohistochemistry, a mixed T cell infiltrate with a predominance of $CD8^+$ lymphocytes is observed, admixed with variably large clusters of $CD123^+$ plasmacytoid dendritic cells. The distribution of plasmacytoid dendritic cells is identical to that seen in LE tumidus, further supporting a close relationship[7].

Differential diagnosis

The differential diagnosis includes the plaque form of polymorphic light eruption, LE tumidus, cutaneous lymphoid hyperplasia (pseudolymphoma), reticular erythematous mucinosis, and cutaneous lymphoma (Fig. 121.3). Subacute cutaneous LE and discoid LE are distinguished by the presence

Fig. 121.1 Lymphocytic infiltrate of Jessner. A Annular erythematous plaque on the cheek. **B** On the central back, pink papules and plaques due to confluence of papules (inset). On palpation, the lesions feel infiltrated. *B, Courtesy Lorenzo Cerroni, MD.*

Downloaded for Anonymous User (n/a) at Egyptian Knowledge Bank from ClinicalKey.com by Elsevier on March 10, 2024. For personal use only. No other uses without permission. Copyright ©2024. Elsevier Inc. All rights reserved.

of secondary changes, including scale, central hypopigmentation, and follicular plugging, along with interface changes histologically. Because in LE tumidus interface changes are sparse, if present at all, distinction from LIJ is impossible when there is increase in dermal mucin. Reticular erythematous mucinosis, which is considered by some as synonymous with LE tumidus, has abundant dermal mucin.

Polymorphic light eruption is associated with sun exposure and usually has a self-limited clinical course. Histologically, papillary dermal edema is often seen and usually there are no clusters of CD123$^+$ plasmacytoid dendritic cells. For some patients, phototesting may provide additional helpful information (see Fig. 121.3).

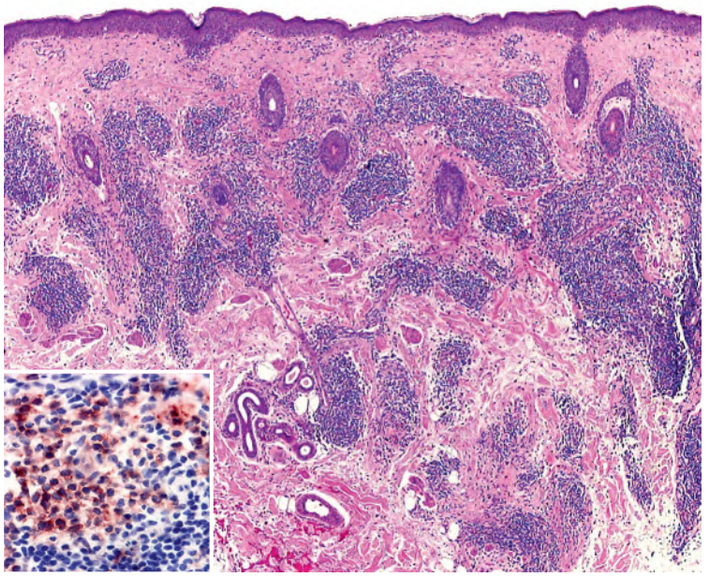

Fig. 121.2 Lymphocytic infiltrate of Jessner. A superficial and deep perivascular infiltrate without an interface component is characteristic. CD123$^+$ plasmacytoid dendritic cells are present within the infiltrate (inset).

Cutaneous lymphomas can have significant clinical and histopathologic overlap with LIJ. If the dermal lymphocytic infiltrate is extensive, immunophenotypic analyses allow distinction between the two entities (see Chs. 119 & 120). Although individual lesions of borderline lepromatous leprosy may resemble LIJ, these patients have a greater number of widespread lesions and bacilli are detected within the dermis by special stains (see Table 75.2).

Treatment

The cutaneous manifestations of LIJ may resolve spontaneously within months to years, without scarring. Oral antibiotics and topical or intralesional corticosteroids have been used with limited success. Up to 50% of patients may improve with hydroxychloroquine. In general, the disorder is resistant to radiation therapy. A crossover study of oral thalidomide (100 mg/day) versus placebo in 25 patients resulted in a clinical response of 76% for thalidomide and 16% for placebo. In isolated case reports, improvement following pulsed dye (595 nm) laser treatment or chemotherapy (for an unrelated malignancy) has been described[8].

Cutaneous Lymphoid Hyperplasia (Pseudolymphoma of the Skin)

Synonyms: ▪ Lymphocytoma cutis ▪ Lymphadenosis benigna cutis (LABC) ▪ Spiegler–Fendt sarcoid ▪ Miliary lymphocytoma

Key features

- Often an isolated, firm, erythematous to violaceous nodule or plaque that measures 1–3 cm in diameter
- Most common on the face and upper trunk
- Mixed dermal infiltrate of lymphocytes, plasma cells, and eosinophils; reactive germinal centers
- Polyclonal inflammatory infiltrate

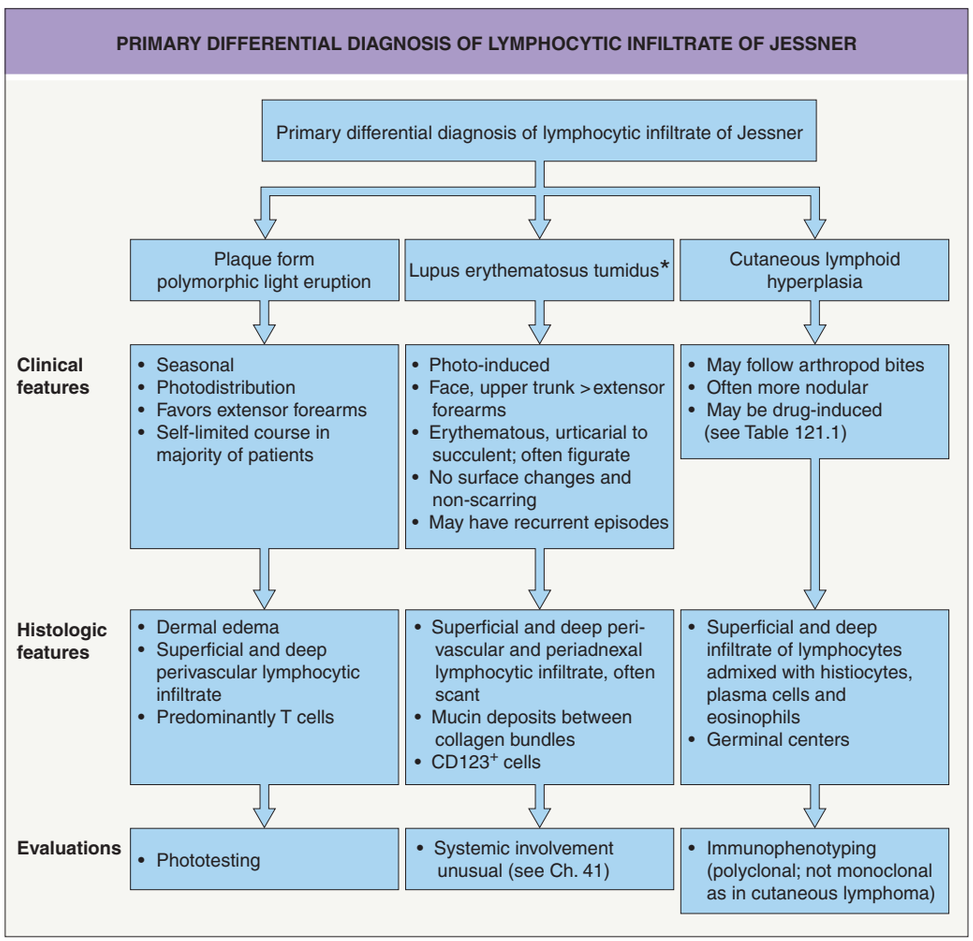

Fig. 121.3 Primary differential diagnosis of lymphocytic infiltrate of Jessner. Reticular erythematous mucinosis (REM) can also be considered in the differential diagnosis; histologically, abundant dermal mucin is observed. *Several authors consider lymphocytic infiltrate of Jessner, LE tumidus, and REM to be similar entities along a clinical spectrum. The differential diagnosis also includes cutaneous T and B cell lymphomas.

Downloaded for Anonymous User (n/a) at Egyptian Knowledge Bank from ClinicalKey.com by Elsevier on March 10, 2024. For personal use only. No other uses without permission. Copyright ©2024. Elsevier Inc. All rights reserved.

History

Cutaneous lymphoid hyperplasia (pseudolymphoma) was first reported by Spiegler in 1894. He described patients who presented with clinical features of a malignant neoplasm but experienced a benign clinical course. Although a characteristic feature is the resemblance to cutaneous lymphoma, there is a spectrum of clinical and histologic findings, reflecting its heterogeneous nature[9].

Epidemiology

Precise data regarding incidence, prevalence, and geographic distribution are lacking. Both children and adults can be affected.

Pathogenesis

Cutaneous lymphoid hyperplasia (CLH) does not represent a single disease, but rather reflects an exaggerated local immunologic reaction to a stimulus, often unrecognized. The possibility of a hapten-driven immunologic response to cells damaged by a direct toxic effect of stimuli has been suggested[10]. Inciting agents include arthropod bites (including ticks and mites), tattoos, metal implants, contact allergens, vaccinations, and medications (Table 121.1)[9–12]. In addition, several infections such as herpes zoster and in Europe Lyme borreliosis have been associated with CLH[9,13,14].

MEDICATIONS ASSOCIATED WITH CUTANEOUS LYMPHOID HYPERPLASIA (PSEUDOLYMPHOMA)	
Anticonvulsants	*Carbamazepine, phenobarbital, phenytoin, ethosuximide, lamotrigine, valproic acid*, ethotoin, *gabapentin*
Antiarrhythmics	*Mexiletine*, procainamide
Antibiotics	*Trimethoprim–sulfamethoxazole, cefixime*, cefuroxime, *nitrofurantoin*, clarithromycin, *vancomycin, rifampin, levofloxacin*
Antidepressants	*Amitriptyline*, desipramine, *fluoxetine*, clompramine, lithium, *sertraline*
Antihistamines	*Cimetidine, ranitidine*, nizatidine, doxepin
Antihypertensives (including diuretics)	*Atenolol*, *captopril*, lisinopril, *diltiazem*, *amlodipine*, *furosemide*, amiloride, losartan, valsartan, clonidine patch, metoprolol
Antineoplastic agents	*Imatinib*, fluorouracil, *gemcitabine*, oxaliplatin, tamoxifen, leucovorin, *ipilimumab, nivolumab*
Antipsychotics	*Chlorpromazine*, perphenazine, thioridazine
Lipid-lowering agents	Gemfibrozil, lovastatin
Nonsteroidal anti-inflammatory drugs (NSAIDs)	*Aspirin*, *ibuprofen*, *naproxen*, *diclofenac*, indomethacin, ketoprofen, sulindac, diflunisal, oxaprozin, nabumetone
Rheumatologic agents	*Allopurinol*, *dapsone*, *sulfasalazine*, methotrexate, gold, D-penicillamine
Sedatives	Benzodiazepines
Steroid hormones	Estrogen, progesterone
Stimulants	Methylphenidate
Targeted immunomodulators ("biologics")	Adalimumab, etanercept, infliximab, secukinumab, tocilizumab
Vaccines*	Hepatitis A, hepatitis B, influenza, quadrivalent HPV, tetanus, varicella–zoster, SARS-CoV-2, early summer meningoencephalitis, GM-CSF-producing tumor cell vaccine, hyposensitization injections
Miscellaneous	Aldesleukin (interleukin-2), bromocriptine, cyclosporine, glatiramer acetate, interferon-alpha, zoledronic acid; black cohosh

*Often aluminum-adsorbed or aluminum-containing.

Table 121.1 Medications associated with cutaneous lymphoid hyperplasia (pseudolymphoma). For patients with the drug reaction with eosinophilia and systemic symptoms (DRESS)/drug-induced hypersensitivity syndrome (DIHS) who have atypical lymphocytes in the blood and skin, the term pseudolymphoma is sometimes applied; however, although this is a separate entity (see Ch. 21), there is overlap. The drugs in *italics* have also been reported to cause DRESS/DIHS. GM-CSF, granulocyte-macrophage colony-stimulating factor; HPV, human papilloma virus. *Adapted from references 9, 10, and 13.*

Clinical features

CLH usually presents as a single, 1–3 cm, firm, erythematous to violaceous plaque or nodule located on the head, neck, or upper extremities (Fig. 121.4A). That said, presentations can vary from multiple clustered papules to larger panniculitis-like nodules (Fig. 121.4B)[9]. The vast majority of lesions lack surface changes such as scale.

Pathology

The histopathological features are variable and the pattern may resemble either a low-grade B cell lymphoma (follicle center lymphoma, marginal zone lymphoma) or a T cell lymphoma, in particular mycosis fungoides, lymphomatoid papulosis (LyP), cutaneous anaplastic large cell lymphoma (cALCL), or subcutaneous panniculitis-like T cell lymphoma[9,13].

In CLH with *B cell predominance*, there is typically a superficial and deep nodular or diffuse infiltrate of lymphocytes, admixed with histiocytes and occasional plasma cells and eosinophils. In florid cases, germinal centers with prominent tingible-body macrophages may be observed (Fig. 121.5). Distinction from follicle center lymphoma can be made on routine histologic sections or with the addition of immunohistochemical stains (Table 121.2). Clonality, based upon IgH gene rearrangements or restricted κ or λ expression, is usually not seen

Fig. 121.4 Cutaneous lymphoid hyperplasia (pseudolymphoma) – clinical presentations. A Oval erythematous infiltrated plaque involving the lateral areola and nipple (inset) which was *Borrelia burgdorferi*-associated. **B**. Several pink and pink–violet papules on the buttocks at the sites of arthropod bites. *Courtesy Lorenzo Cerroni, MD.*

Downloaded for Anonymous User (n/a) at Egyptian Knowledge Bank from ClinicalKey.com by Elsevier on March 10, 2024. For personal use only. No other uses without permission. Copyright ©2024. Elsevier Inc. All rights reserved.

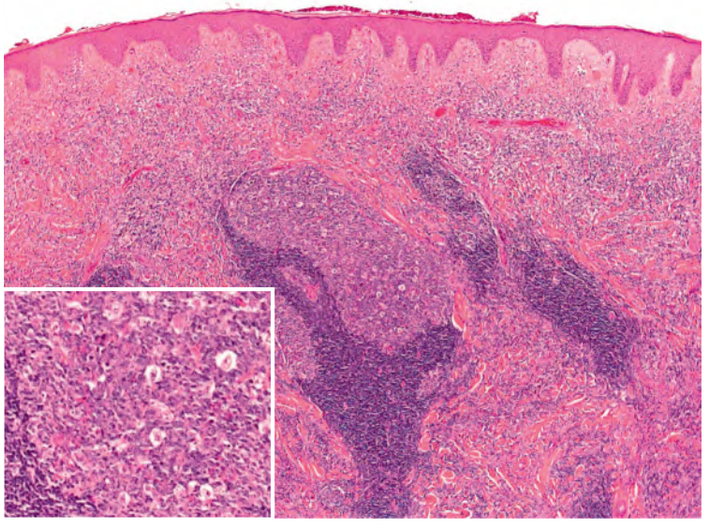

Fig. 121.5 Cutaneous lymphoid hyperplasia (pseudolymphoma) – histopathologic features. Lymphoid cells are seen throughout the dermis in a nodular and diffuse pattern. There is germinal center formation and tingible-body macrophages are present within the germinal centers (inset). The patient had *Borrelia burgdorferi*-associated lymphocytoma cutis. *Courtesy Lorenzo Cerroni, MD.*

MICROSCOPIC DIFFERENCES BETWEEN CUTANEOUS LYMPHOID HYPERPLASIA (PSEUDOLYMPHOMA) AND PRIMARY CUTANEOUS FOLLICLE CENTER LYMPHOMA	
Cutaneous lymphoid hyperplasia (pseudolymphoma)	**Primary cutaneous follicle center lymphoma**
Histologic features	
Mixed cellular infiltrate, including eosinophils and plasma cells	Predominantly lymphocytic infiltrate (eosinophils and plasma cells present in some cases)
Reactive germinal centers	Neoplastic germinal centers
Mantle zone present	No or reduced mantle zone
Tingible-body macrophages present	No tingible-body macrophages
Polarization of follicles with light and dark areas	Monomorphous appearance of follicles without polarization
Immunophenotypic features	
T and B lymphocytes	Predominance of B lymphocytes ($CD20^+$)
Bcl-6^+ cells restricted to lymph follicles	Clusters of Bcl-6^+ cells outside of lymph follicles
Bcl-2 positivity only on T lymphocytes	Bcl-2 positivity on neoplastic B cells (small minority of cases)
High proliferation of germinal centers	Reduced proliferation of germinal centers
Ig genes: polyclonal pattern	Ig genes: monoclonal rearrangement, restricted light chain expression

Table 121.2 Microscopic differences between cutaneous lymphoid hyperplasia (pseudolymphoma) and primary cutaneous follicle center lymphoma. Ig, immunoglobulin.

in pseudolymphomas (see Fig. 119.10)[9,14]. PCR analysis for *Borrelia burgdorferi* DNA is positive in *Borrelia*-associated lymphocytoma cutis and pseudolymphomatous acrodermatitis chronica atrophicans[9,14].

In *T cell-predominant* infiltrates, $CD4^+$ T helper lymphocytes are commonly observed within the dermis, admixed with a minority of $CD8^+$ cytotoxic/suppressor T cells. An accompanying population of B lymphocytes is usually present. A mycosis fungoides-like pattern is most often encountered in drug-induced pseudolymphomas (see Table 121.1). Histologically, epidermotropism, spongiosis, vacuolar degeneration of the basal layer, papillary dermal edema, and red cell extravasation may be seen. Prominent papillary dermal fibrosis, which can be seen in mycosis fungoides, is absent, but T cell clonality may be present.

$CD30^+$ pseudolymphomas include persistent arthropod bite reactions, drug reactions, and the atypical lymphoid infiltrates associated with cutaneous poxvirus infections (e.g. molluscum contagiosum, orf). Additional findings related to the underlying disorder can aid in diagnosis, and there is polyclonal rearrangement of the TCR genes[9,13].

Differential diagnosis

Pseudolymphomas may be difficult to differentiate from *cutaneous lymphomas* (see Pathology section). Although the presence of clonality may aid in distinguishing reactive from neoplastic processes, it should not be used alone to establish malignancy. In addition to clinicopathologic correlation, longitudinal evaluation plays a key role in making this distinction.

Acral pseudolymphomatous angiokeratoma of children (APACHE), originally thought to represent a vascular nevus, is now categorized as a pseudolymphoma. In contrast to other pseudolymphomas, it favors the extremities of children between the ages of 2 and 16 years, usually presenting as a unilateral grouping of small, red to violet, "angiomatous" papules. Histologically, there is a dermal infiltrate of lymphocytes, histiocytes, and plasma cells accompanied by prominently thickened capillaries[9].

Kikuchi–Fujimoto disease, also known as histiocytic necrotizing lymphadenitis, is an idiopathic systemic inflammatory disease most commonly seen in young adult women. It is associated with a variety of viral and bacterial infections (e.g. Epstein–Barr virus, cytomegalovirus) as well as autoimmune diseases (e.g. systemic LE). In addition to fever, malaise, weight loss, and gastrointestinal symptoms, patients develop cervical lymphadenopathy. Histologically, involved lymph nodes show infiltration of plasmacytoid dendritic cells in the paracortical area and later histiocytes and necrosis in the absence of an identifiable pathogen. Cutaneous findings, present in 40% of patients, include acneiform eruptions, urticaria, ulcers, and indurated erythematous plaques. Histologically, dense superficial and deep perivascular lymphohistiocytic infiltrates with nuclear debris (in the absence of neutrophils) are seen; interface changes are commonly present[15,16].

In *"pseudolymphomatous folliculitis"*, there is typically a solitary facial nodule that is due to a predominantly perifollicular and periadnexal dermal infiltrate. It is unclear whether these cases really represent an entity or, as the authors of this chapter believe, a mixture of different reactive conditions. The infiltrate is typically mixed with a predominance of T or B cells that may have cellular atypia; granulomas are variably present[17,18]. There is irregular hyperplasia and distortion of the follicular epithelium, with blurring of the dermal–epidermal junction, and infiltrates of $CD1a^+$/$S100^+$ mononuclear cells surround and infiltrate these distorted follicles. This entity should be distinguished from primary cutaneous $CD4^+$ small/medium-sized pleomorphic T cell lymphoproliferative disorder, which is characterized by more pronounced pleomorphism of the cells[17–19]. Distinction from pilotropic mycosis fungoides is based on the presence of a mixed infiltrate of T and B lymphocytes as well as absent or minimal folliculotropism in pseudolymphomatous folliculitis.

Cutaneous and systemic plasmacytosis is a benign condition of unknown etiology observed primarily in Asians, especially those of Japanese ancestry. It is characterized by multiple, reddish-brown, infiltrated maculopapules and plaques, most often on the trunk. Histopathologically, variably dense superficial and deep perivascular infiltrates composed predominantly of mature polyclonal plasma cells are seen[9,20,21]. The plasmacytosis may be accompanied by anemia, B symptoms, and hypergammaglobulinemia, as well as lymphadenopathy, hepatosplenomegaly, interstitial pneumonia, and mesangial proliferative glomerulonephritis. A reactive dysfunction of plasma cells triggered by various stimuli has been postulated[22]. As in Castleman disease, there is an elevation in circulating/tissue IL-6, but in the absence of HHV-8 infection[9,20,21].

Intralymphatic histiocytosis (formerly intravascular histiocytosis) has been observed most often in patients with rheumatoid arthritis or metallic orthopedic implants[23]. It has also been reported in association with severe osteoarthritis, solid organ malignancies (e.g. breast cancer), lymphedema, and various skin disorders (e.g. Morbihan disease, granulomatous cheilitis, healing cellulitis). Clinically, intralymphatic histiocytosis usually presents with poorly defined erythematous plaques that may have a reticular pattern (Fig. 121.6A). The lesions can co-localize anatomically with underlying disorders or implants. Histologically, collections of epithelioid histiocytes are seen within dilated lymphatic

Downloaded for Anonymous User (n/a) at Egyptian Knowledge Bank from ClinicalKey.com by Elsevier on March 10, 2024. For personal use only. No other uses without permission. Copyright ©2024. Elsevier Inc. All rights reserved.

vessels – findings that resemble intravascular large cell lymphoma (Fig. 121.6B)[9,23]. The histiocytes are CD68$^+$, S100$^-$, and CD1a$^-$; the endothelial cells express D2-40. Intralymphatic histiocytosis can be differentiated from reactive angioendotheliomatosis and other intravascular proliferations via immunohistology[9,23].

Additional examples of pseudolymphoma are outlined in Table 121.3.

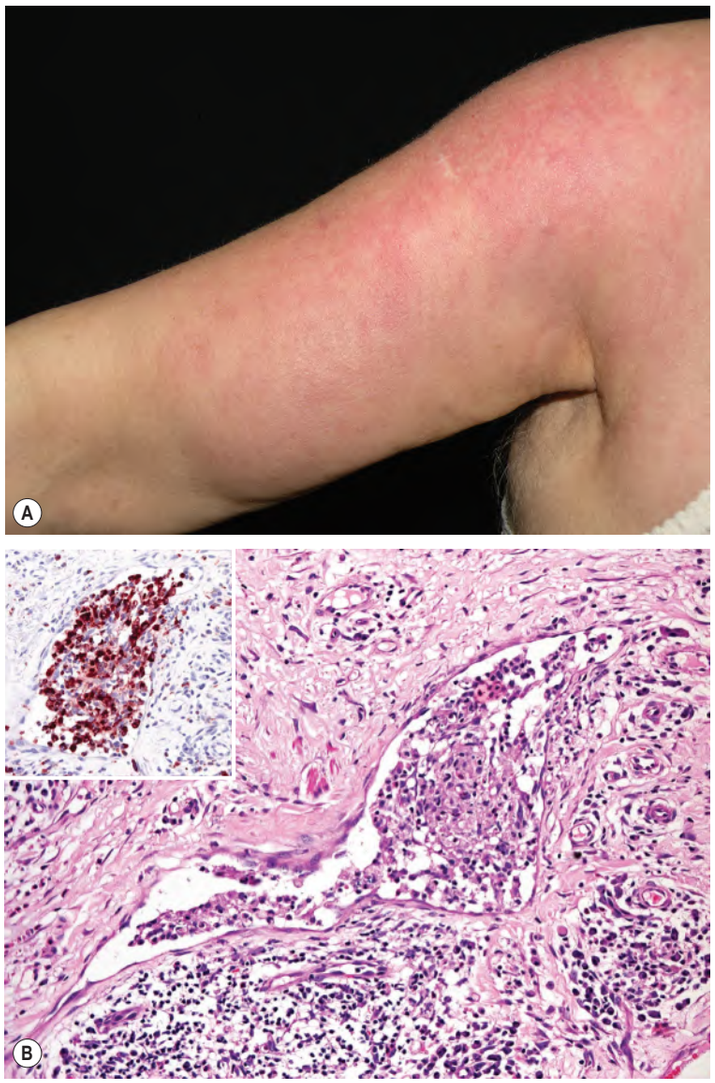

Fig. 121.6 Intralymphatic histiocytosis. A Reticulated erythematous plaque of the upper arm and shoulder in a patient with rheumatoid arthritis. **B** Dilated dermal lymphatic vessel filled with histiocytes, admixed with some leukocytes, and surrounded by a lymphoplasmacytic perivascular infiltrate; note CD68 positivity of the histiocytes (inset). *A, Courtesy Luis Requena, MD; B, Courtesy Lorenzo Cerroni, MD.*

Treatment

CLH is a benign, reactive condition and it should be treated conservatively. Spontaneous resolution may occur without scarring, and performance of a biopsy, even if partial, can be followed by spontaneous regression. Medication-associated CLH usually resolves after drug discontinuation[12]. Topical and intralesional corticosteroids or topical tacrolimus may lead to improvement. For persistent lesions, simple excision, cryosurgery, laser ablation, photodynamic therapy, phototherapy, and radiation therapy are other options. Hydroxychloroquine, thalidomide, and intralesional or intravenous rituximab have also been reported as successful therapies[17,24]. For *Borrelia*-associated pseudolymphoma, appropriate antibiotics are administered (see Ch. 19).

CUTANEOUS EXTRAMEDULLARY HEMATOPOIESIS

Key features

- Evidence of bone marrow dysfunction
- Most common associations are TORCH (*t*oxoplasmosis, *o*ther agents, *r*ubella, *c*ytomegalovirus and *h*erpes simplex virus) infections in neonates and myelofibrosis in adults
- Widely disseminated erythematous to violaceous papules and nodules, with neonatal form referred to as "blueberry muffin baby"
- Diffuse dermal infiltrate of immature erythrocytes, leukocytes, and megakaryocytes

Epidemiology

Cutaneous extramedullary hematopoiesis (CEMH) is a reflection of bone marrow dysfunction and is most commonly seen in neonates following congenital infections. It may also occur in adults with myelodysplasia or myeloproliferative neoplasms (myelofibrosis, polycythemia vera, essential thrombocythemia)[9], as well as following splenectomy for myeloproliferative neoplasms. A very rare association is primary hypertrophic osteoarthropathy[25].

Pathogenesis

CEMH occurs normally during early embryogenesis and abates prior to birth. Thereafter, it occurs only as a secondary phenomenon in response to altered bone marrow function. Dermal hematopoiesis reflects an expansion of follicular, dermal, or circulating hematopoietic stem cells and is probably induced by cytokines (e.g. IL-3, G-CSF, TGF-β)[25]. Rarely, in otherwise healthy individuals, primary cutaneous neoplasms such as pilomatricomas, nevus sebaceus, hemangiomas, and pyogenic granulomas may be associated with localized CEMH[9,25,26].

Clinical Features

The clinical presentation consists of erythematous to violaceous papules and nodules which may ulcerate. When widely disseminated in

ENTITIES THAT CAN MIMIC CUTANEOUS T AND B CELL LYMPHOMAS		
More common	**Uncommon**	**Rare**
• Persistent arthropod bites, scabies • *Borrelia* infections, in particular lymphocytoma cutis and acrodermatitis chronica atrophicans (Europe) • CD30$^+$ reactive lymphoid infiltrates in the context of cutaneous infections (e.g. herpes simplex, herpes zoster, molluscum contagiosum) • Drug eruptions (lichenoid, lymphomatoid) (see Table 121.1) • Lichenoid (lymphomatoid) keratosis • Pseudolymphomatous infiltrates in cutaneous lupus erythematosus • Lichen sclerosus of genital skin	• Lymphomatoid contact dermatitis • Pigmented purpura, lichenoid variant • Pityriasis lichenoides (acute or chronic forms) • Pseudolymphomatous atopic dermatitis • Pseudolymphomatous folliculitis • Pseudolymphomatous reactions to tattoo pigments • Syphilis, primary and secondary	• Actinic reticuloid • APACHE (acral pseudolymphomatous angiokeratoma of children) • Cutaneous IgG4-related disease* • Cutaneous plasmacytosis • Hydroa vacciniforme • Intralymphatic histiocytosis • Kikuchi–Fujimoto disease • Lobular panniculitis in children with congenital immunodeficiencies • Pseudolymphomatous reactions to vaccinations • Vitiligo (inflammatory stage)
*Increased IgG4-positive plasma calls and sclerotic stroma; can also be seen in granuloma faciale-like lesions.		

Table 121.3 Entities that can mimic cutaneous T and B cell lymphomas. These entities are sometimes referred to as pseudolymphomas. For details see reference 9.

Downloaded for Anonymous User (n/a) at Egyptian Knowledge Bank from ClinicalKey.com by Elsevier on March 10, 2024. For personal use only. No other uses without permission. Copyright ©2024. Elsevier Inc. All rights reserved.

neonates, it leads to the classic "blueberry muffin baby" (Fig. 121.7)[25]. This can be seen in association with congenital viral infections and prenatal anemias (Table 121.4). Dermal hematopoiesis is most often seen with rubella and cytomegalovirus, and serologic titers for TORCH infections can aid in diagnosis.

Pathology

CEMH is characterized by a dermal infiltrate of immature white and red blood cell precursors (erythroblasts) and megakaryocytes, centered around vessels of the superficial vascular plexus. It may also extend into the deeper reticular dermis and exhibit a diffuse pattern. All three hematopoietic cell lines are present in varying ratios, depending upon the underlying disease process.

Differential Diagnosis

The clinical differential diagnosis in neonates is outlined in Table 121.4 and in adults the possibility of leukemia cutis needs to be considered. Histologically, the differential diagnosis is limited. Distinguishing CEMH from disseminated congenital leukemia cutis and neonatal neuroblastoma is important. Whereas all three hematopoietic cell lines (erythrocytes, leukocytes, and megakaryocytes) are represented in CEMH, there is an atypical, monomorphous infiltrate of immature leukocytes in leukemia cutis.

Fig. 121.7 Extramedullary hematopoiesis. "Blueberry muffin baby" secondary to congenital rubella. *Courtesy Eugene Mirrer, MD.*

DIFFERENTIAL DIAGNOSIS OF "BLUEBERRY MUFFIN BABY"
Disseminated extramedullary hematopoiesis

• Congenital TORCH infections
  • Toxoplasmosis
  • Other – coxsackievirus, parvovirus
  • Rubella
  • Cytomegalovirus
• Severe hemolytic anemias
  • Congenital spherocytosis
  • Rhesus hemolytic disease
  • ABO incompatibility
• Other causes of severe anemia
  • Twin–twin transfusion
  • Chronic fetomaternal hemorrhage
  • Severe internal bleeding (e.g. intracranial)
  • Congenital leukemia or myelodysplasia
• Aicardi–Goutières syndrome

Neoplastic infiltration
• Congenital leukemia cutis, transient myeloproliferative disorder • Neonatal neuroblastoma, peripheral primitive neuroectodermal tumor • Congenital Langerhans cell histiocytosis, disseminated xanthogranulomas (early lesions), hemophagocytic lymphohistiocytosis • Congenital alveolar rhabdomyosarcoma • Infantile myofibromatosis • Multifocal infantile hemangiomas, other vascular lesions (e.g. multifocal lymphangioendotheliomatosis, glomuvenous malformations)

Table 121.4 Differential diagnosis of "blueberry muffin baby". TORCH, toxoplasmosis, other agents, rubella, cytomegalovirus, and herpes simplex virus.

Treatment

Treatment of the underlying bone marrow dysfunction results in reversal of the cutaneous process. Spontaneous resolution can occur with some viral infections.

MALIGNANT HEMATOPOIETIC INFILTRATES

Leukemia Cutis

Key features

- Pink to red–brown or purple papules and nodules; hemorrhagic ulcers
- Diffuse dermal infiltrate of neoplastic leukocytes
- Monomorphic immature precursor cells in some types

Epidemiology

Multiple types of leukemia exist, each with its own epidemiologic characteristics. Acute lymphoblastic leukemia (ALL) tends to be a neoplasm of childhood. Acute myelogenous leukemia (AML) and chronic myelogenous leukemia (CML) occur primarily in adults, and chronic lymphocytic leukemia (CLL) and hairy cell leukemia are most common in elderly patients[28,29]. Development of CML-associated leukemia cutis can be a harbinger of blast transformation[9], while the development of leukemia cutis in a patient with myelodysplastic syndrome (MDS) points to progression to AML[27]. In some patients with MDS, cutaneous lesions with an accumulation of benign-appearing dendritic and myeloid cells and a chronic course have been described. Leukemia cutis is most commonly seen in patients with *NPM1*-mutated AML and less often in CLL[9,28,29a,29b].

Pathogenesis

Specific chromosomal abnormalities are associated with particular subtypes of leukemia. The Philadelphia chromosome, the primary diagnostic feature of CML, represents a translocation between chromosomes 9 and 22 [t(9;22)]. This translocation results in fusion of the two genes *BCR* and *ABL*, with constitutive activation of the tyrosine kinase activity of the fusion oncoprotein. It is this kinase activity that is selectively inhibited by imatinib mesylate (Gleevec®). Additionally, 95% of patients with promyelocytic leukemia have a t(15;17) translocation, which leads to abnormal expression of a fusion retinoic acid receptor that is the target of all-*trans* retinoic acid therapy.

A variety of non-random chromosomal abnormalities exists in ALL and AML that can influence prognosis, and in AML mutations in particular genes can be favorable (e.g. *CEBPA*) or unfavorable (e.g. *FLT3*-ITD)[29a,29b]. *NPM1* is the most frequently mutated gene in patients with AML and normal cytogenetics; as noted previously, *NPM1*-mutated AML is the subtype most commonly associated with leukemia cutis[29a,29b]. Table 121.5 outlines the relationship between specific abnormalities and prognosis in CLL[28,29].

RELATIONSHIP BETWEEN SPECIFIC MOLECULAR ABNORMALITIES AND PROGNOSIS IN CHRONIC LYMPHOCYTIC LEUKEMIA	
Molecular abnormalities	**Prognosis**
Chromosomal	
13q deletion	Favorable
Trisomy 12	Intermediate
11q deletion	Poor
17p deletion	Poor
Genetic mutations	
TP53	Poorest
Other	
Unmutated *IGHV* genes	Poor

Table 121.5 Relationship between specific molecular abnormalities and prognosis in chronic lymphocytic leukemia. *TP53* is located on chromosome 17p and 17p deletions often involve *TP53*. *IGHV*, immunoglobulin heavy chain variable region gene.

Downloaded for Anonymous User (n/a) at Egyptian Knowledge Bank from ClinicalKey.com by Elsevier on March 10, 2024. For personal use only. No other uses without permission. Copyright ©2024. Elsevier Inc. All rights reserved.

Clinical features

Leukemia can lead to nonspecific reactive skin lesions (Table 121.6) or specific infiltrates. The latter most commonly present as multiple, generalized or localized, firm papules and nodules that vary in color from pink to red–brown to purple. The papulonodules often become hemorrhagic and thrombocytopenia usually plays a role in this associated hemorrhage. Ulcerative and rarely bullous lesions occur. Leukemia cutis can develop in any location, but the head, neck, and trunk are most commonly involved (Fig. 121.8A). Leukemic infiltrates may arise at sites of trauma or scars.

Rarely, myelogenous leukemias may present with dermal or subcutaneous nodules known as myeloid sarcomas or chloromas. These skin lesions may precede the development of systemic leukemia by months.

"INFLAMMATORY" DISORDERS ASSOCIATED WITH LEUKEMIAS AND MYELODYSPLASTIC SYNDROMES	
Cutaneous disorder	**Associated leukemias and MDS**
Neutrophilic dermatoses	
Sweet syndrome, including histiocytoid variant*	AML > MDS, CML, hairy cell leukemia, CNL > ALL, CLL
Pyoderma gangrenosum†	AML, MDS, CML, hairy cell leukemia > ALL, CLL
Neutrophilic eccrine hidradenitis	AML ≫ ALL, CML, CLL
Reactive erythemas	
Eosinophilic dermatosis of hematologic malignancy (including exaggerated reactions to arthropod bites)	CLL >>> AML, CML
Erythroderma	CLL‡
Facial erythema and edema	T cell prolymphocytic leukemia
Vasculitis	
Polyarteritis nodosa	Hairy cell leukemia ≫ CMML, MDS
Vasculitis (small vessel/ leukocytoclastic)	Hairy cell leukemia, CLL > AMML, ALL, MDS
Erythema elevatum diutinum	Hairy cell leukemia, CLL
Panniculitis	
Erythema nodosum¶	AML, CML, CMML
Other panniculitides§	Hairy cell leukemia, AML, CMML
Other	
Urticaria	CLL, hairy cell leukemia
Erythema multiforme‖	CLL
Paraneoplastic pemphigus	CLL
Recalcitrant adult-onset eczema	CLL (T cell)
Acral ischemia with lividity	CML#
Reactive granulomatous dermatitis including interstitial granulomatosis dermatitis, sarcoidal, GA-like	MDS
Pernio	CMML

*Histiocytoid variant linked to hematologic malignancies and MDS.
†Especially bullous.
‡Many probably represented Sézary syndrome.
¶Isolated case reports; may occur concomitantly with Sweet syndrome and some cases better classified as subcutaneous Sweet syndrome.
§Sweet syndrome may have a subcutaneous component.
‖May have represented paraneoplastic pemphigus.
#Leukostasis/hyperleukocytosis syndrome.

Table 121.6 "Inflammatory" disorders associated with leukemias and myelodysplastic syndromes[18–21]. Most patients with CML who develop vitiligo-like changes are receiving imatinib. Infiltrates of leukemic cells (CLL > AML) may be seen in post-herpes zoster scars (see Table 80.7). ALL, acute lymphoblastic leukemia; AML, acute myelogenous leukemia; AMML, acute myelomonocytic leukemia; CLL, chronic lymphocytic leukemia; CML, chronic myelogenous leukemia; CMML, chronic myelomonocytic leukemia; CNL, chronic neutrophilic leukemia; GA, granuloma annulare; MDS, myelodysplastic syndrome.

Gingival hyperplasia, secondary to leukemic infiltrates, favors acute monocytic or acute myelomonocytic leukemia, especially those with *NPM1* mutations.

In one series, cutaneous eruptions of leukemia accounted for 30% of all skin biopsy specimens in patients with leukemia[30]. Other diagnoses included GVHD, drug eruptions, infectious processes, purpura, and small vessel vasculitis. In most patients with acute leukemia, cutaneous lesions are present at the time of diagnosis or recurrence, but occasionally, skin involvement precedes the appearance of leukemia in the peripheral smear ("aleukemic" leukemia cutis). Rarely, leukemia cutis predates apparent bone marrow involvement by months or even years.

Of note, asymptomatic dermal leukemic infiltrates of CLL may be evident in biopsy specimens of primary cutaneous neoplasms (e.g. squamous cell carcinoma) and inflammatory or infectious disorders such as herpes simplex and herpes zoster viral infections. This phenomenon indicates that these neoplastic cells retain the capability to respond to chemotactic stimuli and migrate into tissues (inflammatory oncotaxis)[31,32].

The characteristics of the different forms of leukemia cutis are summarized in Table 121.7.

Pathology

Histologic features of leukemia cutis vary with the type of leukemia. The neoplastic infiltrates may be perivascular, interstitial, nodular, and/or diffuse; occasionally, they densely surround the eccrine glands[30–32]. Diagnosis is more difficult when the perivascular and periadnexal infiltrates are sparse and mimic inflammatory disorders[32].

AML represents a neoplastic proliferation of immature myeloid cells and encompasses multiple subtypes[29a,29b]. In general, the neoplastic cells recapitulate myeloid precursor cells in their immature stages of development (Fig. 121.8B). In many cases, cytoplasmic granules can be found. The most common forms of AML that involve the skin and present *de novo* (without previous evidence of systemic disease) are the more differentiated subtypes – acute myelomonocytic and acute monocytic leukemia. Immunohistochemically, the infiltrates of AML are positive for myeloid markers such as myeloperoxidase, CD33, CD34, and CD68 and are usually negative for CD123[9,29a,29b].

In CML, there is a range of myeloid precursors, including promyelocytes, metamyelocytes, bands, and mature neutrophils. Although cutaneous lesions of CML are rare, they are typically seen in patients with chronic myelomonocytic leukemia and are associated with blast transformation and a poor prognosis[9,29a,29b].

ALL represents a clonal expansion of immature lymphocytes, most commonly of B cell lineage and less commonly T cell lineage. Rarely, cytoplasmic granularity may be present, and this corresponds with a precursor B cell immunophenotype. Cells of ALL may be difficult to identify in skin biopsy specimens and immunostaining for terminal deoxytransferase may prove helpful[9,28,29].

Cutaneous CLL is characterized by a dense infiltrate of uniform-appearing, small, round lymphocytes of B cell lineage (Fig. 121.9). The cells appear mature, but the monomorphous nature and paucity of other cell types within the infiltrate suggest a leukemic infiltrate. The lymphocytes often surround adnexal and vascular structures. Immunohistochemically, CLL shows positivity for LEF1, CD5 (variable), CD20, and CD23[9,28,31,33].

Differential diagnosis

The clinical differential diagnosis includes cutaneous lymphoma, cutaneous lymphoid hyperplasia, infectious emboli, vasculitis, panniculitis, and drug eruptions. The histologic differential diagnosis of leukemia cutis depends upon the type of leukemia present. Distinguishing some cases of leukemia cutis from lymphomas involving the skin can be difficult. For myeloid leukemias, the differential diagnosis includes mainly extramedullary hematopoiesis (see above), diffuse large cell lymphomas, and histiocytoid Sweet syndrome. Of note, in some cases of histiocytoid Sweet syndrome[34] neoplastic cells of AML may be present within the infiltrate[35].

Treatment

No specific treatment for leukemia cutis currently exists. The cutaneous eruptions typically resolve following successful treatment of the leukemia.

Downloaded for Anonymous User (n/a) at Egyptian Knowledge Bank from ClinicalKey.com by Elsevier on March 10, 2024. For personal use only. No other uses without permission. Copyright ©2024. Elsevier Inc. All rights reserved.

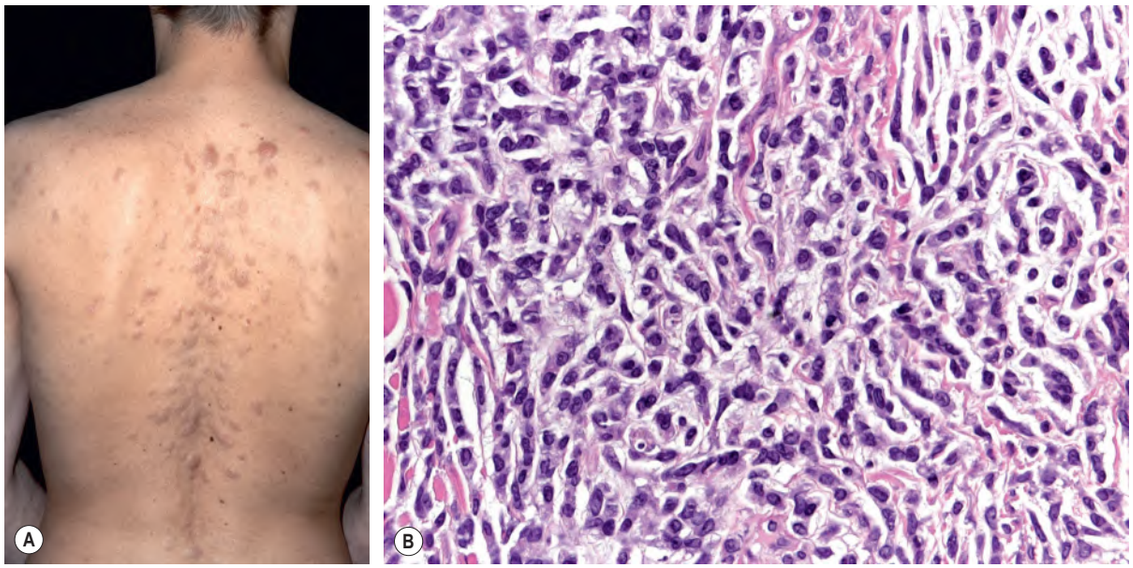

Fig. 121.8 Leukemia cutis. A Numerous violet–brown papules and plaques on the back of a patient with acute myelogenous leukemia. **B** Histologically, an infiltrate of atypical monocytoid cells characterized by nuclear pleomorphism and relatively abundant cytoplasm is seen.

CHARACTERISTICS OF DIFFERENT TYPES OF LEUKEMIA CUTIS				
Type of leukemia	**ALL**	**CLL**	**AML**	**CML**
Characteristic age	Between 2 and 5 years of age	Late 7th decade or older	Variable, most commonly 7th decade	Variable, most commonly after 50 years of age
Presenting anatomic site	Predominantly head and neck	Generalized; may appear at sites of infection (e.g. herpes zoster) or neoplasms (e.g. SCC)	Generalized	Variable
Clinical course	Aggressive	Indolent	Aggressive	Intermediate*
Subtype of leukemia/ immunophenotype	• 85%: B cell ALL (CD19$^+$, TdT$^+$, CD20$^+$, CD5$^+$, CD10$^+$, CD22$^+$, CD79a$^+$, PAX-5$^+$) • 15%: T cell ALL (TdT$^+$, CD1a$^+$, CD2$^+$, CD3c$^+$, CD4$^+$, CD5$^+$, CD7$^+$, CD8$^+$)	• B cell type (CD5$^+$, CD23$^+$, LEF1$^+$, CD20$^+$)	• CD33$^+$, CD34$^+$, myeloperoxidase$^+$ > CD13$^+$, CD68$^+$ • Markers may not be present if undifferentiated	• Most commonly, CMML • Cutaneous involvement associated with blast transformation
Incidence of cutaneous involvement	• Rare	• Not infrequent • Usually an incidental finding in biopsy specimens†	• More common with *NPM1*-mutated AML • May be presenting sign	• Rare
Time of presentation	• Late	• Late	• Early or late • May be the first sign of recurrence after treatment	• Late
Clinical appearance‡	• Large, non-ulcerated tumors • Nonspecific papulonodules	• Nonspecific papulonodules	• Nonspecific papulonodules	• Nonspecific papulonodules

*When acceleration or blast transformation occurs, becomes aggressive.
†Including primary cutaneous neoplasms (e.g. SCC), inflammatory disorders, and infectious diseases (see text).
‡Less common presentations reviewed in the text.

Table 121.7 Characteristics of different types of leukemia cutis. ALL, acute lymphoblastic leukemia; AML, acute myelogenous leukemia; CLL, chronic lymphocytic leukemia; CML, chronic myelogenous leukemia; CMML, chronic myelomonocytic leukemia; SCC, squamous cell carcinoma; TdT, terminal deoxytransferase.

Cutaneous Hodgkin Lymphoma

Synonyms: ▪ Cutaneous Hodgkin disease ▪ Cutaneous Hodgkin's disease

Key features

- Advanced stage in most patients with skin involvement
- Dermal nodules and plaques, sometimes ulcerated
- Dense dermal infiltrate with lymphocytes and eosinophils
- Atypical cells (lacunar cells, Reed–Sternberg cells)

History

In 1832, Thomas Hodgkin described a series of patients with lymphadenopathy, splenomegaly, and weight loss, all of whom died of their disease. Wilks reported a subsequent series of patients in 1885, and designated the illness Hodgkin's disease.

Epidemiology

Cutaneous involvement by Hodgkin lymphoma (HL) is rare[9,36–38]. In one large study, only 0.5% of patients with HL had cutaneous involvement[38], primarily in the setting of advanced disease and serving as a marker of poor prognosis. The existence of true primary cutaneous HL is debatable[9].

The incidence of HL peaks during early adulthood, with a second, smaller peak in the sixth decade. Of note, compared to the general population, mycosis fungoides and LyP occur at higher rates in patients with HL[37,39]. This reflects the increased incidence of non-Hodgkin lymphomas in general in HL patients. The underlying reason for this phenomenon is not known.

Pathogenesis

Approximately 30% of patients with classic HL (see below) have Epstein–Barr virus (EBV) DNA within the pathognomonic Reed–Sternberg tumor cells. The precise role of EBV in HL pathogenesis is not known[40]. In classic HL, the Reed–Sternberg cells represent the malignant population and are usually derived from B cell lymphocytes.

Downloaded for Anonymous User (n/a) at Egyptian Knowledge Bank from ClinicalKey.com by Elsevier on March 10, 2024. For personal use only. No other uses without permission. Copyright ©2024. Elsevier Inc. All rights reserved.

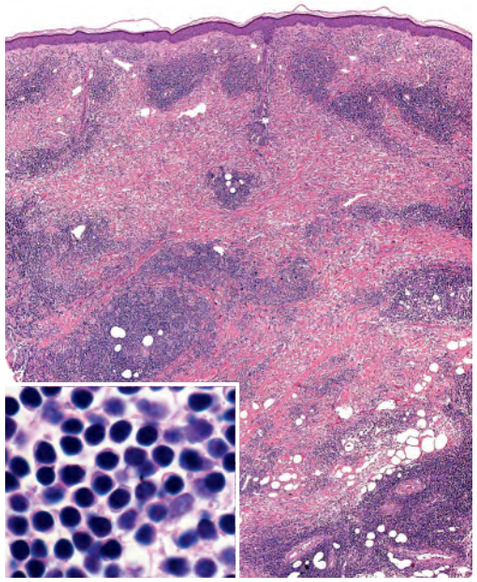

Fig. 121.9 Chronic lymphocytic leukemia (CLL). Nodular-diffuse infiltrates of lymphocytes are present within the entire dermis and superficial subcutis. The cells in CLL are small, monomorphous, hyperchromatic lymphocytes that lack significant cytologic atypia (inset). *Courtesy Lorenzo Cerroni, MD.*

Fig. 121.10 Blastic plasmacytoid dendritic cell neoplasm. Multiple firm violaceous nodules and plaques on the back. The scale-crust is at the site of a previous biopsy. *Courtesy Lorenzo Cerroni, MD.*

Clinical features

Classic HL includes the nodular sclerosing (most common), mixed cellularity, and lymphocyte-depleted forms of the disease, and it is characterized histologically by the presence of Reed–Sternberg cells. A small minority of patients have a non-classic, more indolent form of the disease, referred to as nodular lymphocyte-predominant HL.

Cutaneous involvement usually consists of multiple papulonodules or plaques in a patient with known, advanced disease. The trunk is the most common site of involvement[38], and lesions often appear in sites distal to affected lymph nodes. Lymphadenopathy, splenomegaly, and constitutional symptoms (e.g. fevers, chills, night sweats) are additional signs and symptoms.

In 20%–50% of patients with HL, paraneoplastic cutaneous disorders can develop. These include primary pruritus, acquired ichthyosis, persistent dermatitis, widespread eczema craquelé, hyperpigmentation, and occasionally, erythema nodosum[37].

Pathology

The histologic features of cutaneous HL are similar to those of affected lymph nodes. A nodular or diffuse dermal infiltrate consisting of lymphocytes admixed with eosinophils and plasma cells is present; epidermotropism is not seen. Depending upon the histologic subtype, Reed–Sternberg cells (or mononuclear variants) and lacunar cells may be present. The latter, most common in the nodular sclerosing subtype of HL, are large cells with abundant eosinophilic cytoplasm. The retraction of this cytoplasm from adjacent cells during fixation gives rise to a giant cell residing within a clear space. Areas of dermal sclerosis may be seen and extension into the subcutaneous fat is common.

Reed–Sternberg cells express CD30, fascin, and CD15, but not CD45RB (leukocyte common antigen) or CD20. They are positive for PAX-5, MUM-1, and in ~30% of cases, EBV (EBER-1). The background infiltrate of lymphocytes is composed predominantly of T cells[32]. In non-classic lymphocyte-predominant HL, the malignant cells stain positively for CD20[9,29].

Differential diagnosis

The histologic differential diagnosis of HL includes cALCL and LyP, both of which have cells that stain positively for CD30 (see Ch. 120). Clinicopathologic correlation is important in differentiating between these entities. Both LyP and cALCL can present with variably ulcerated papules and nodules, but patients with LyP do not have evidence of systemic involvement and crops of their lesions appear and then spontaneously resolve. Sheets of atypical $CD30^+$ cells are usually seen in cALCL, and the cells in LyP and most cases of cALCL do not stain positively for CD15 or PAX-5[9].

Treatment

Patients with stage IV HL, who may have secondary cutaneous disease, have a cure rate of ~70%–80% following combination chemotherapy. Treatments for recurrent disease include salvage chemotherapy, autologous HSCT, and anti-CD30 (brentuximab) and anti-PD-1 antibodies[41].

Blastic Plasmacytoid Dendritic Cell Neoplasm

Synonyms: ▪ $CD4^+/CD56^+$ hematodermic neoplasm ▪ Blastic NK cell lymphoma

Key features

- Single to multiple, non-tender papules, nodules, and plaques that can resemble bruises
- At initial presentation, skin is the most common site of involvement
- Dense perivascular infiltrate of uniformly atypical, medium-sized mononuclear cells
- Immunohistochemical profile: $CD123^+$, $CD4^+$, $CD56^+$, $TCF4^+$
- T cell receptor (TCR) and IgH gene rearrangements are not present
- Predictable good initial response to chemotherapy, but relapses common and poor survival

History and epidemiology

In 1994, blastic plasmacytoid dendritic cell neoplasm (BPDCN) was described by Adachi et al.[42] as a $CD4^+/CD56^+$ lymphoma presenting predominantly in the skin. Initially classified as blastic NK cell lymphoma due to its CD56 expression, this rare tumor was subsequently reclassified, first as a hematodermic neoplasm and then as a neoplasm of plasmacytoid dendritic cells[43]. Currently, BPCDN is listed as a myeloid-related specific entity in both the 2022 International Consensus Classification of Myeloid Neoplasms and in the recent WHO classification of Myeloid and Histiocytic/Dendritic Neoplasms[29a,29b,44].

BPDCN is a disease of adults, usually those >50 years of age, but pediatric cases have been reported. The male-to-female ratio is 3 : 1.

Pathogenesis

BPDCN represents a malignant proliferation of plasmacytoid dendritic cells. These cells produce large amounts of type I interferons (IFN), specifically IFN-α, and they express several Toll-like receptors (e.g. TLR7, TLR9), making them critical in the defense against viruses and other pathogens[29a,29b,45].

Clinical features

Clinically, BPDCN presents as solitary or multiple, non-tender, variably pruritic, erythematous to violaceous papules, plaques, or nodules that can resemble bruises (Fig. 121.10). Ulceration is uncommon. In most patients, the skin is the presenting site of involvement. However, further evaluation usually reveals subclinical regional lymph node, peripheral

Downloaded for Anonymous User (n/a) at Egyptian Knowledge Bank from ClinicalKey.com by Elsevier on March 10, 2024. For personal use only. No other uses without permission. Copyright ©2024. Elsevier Inc. All rights reserved.

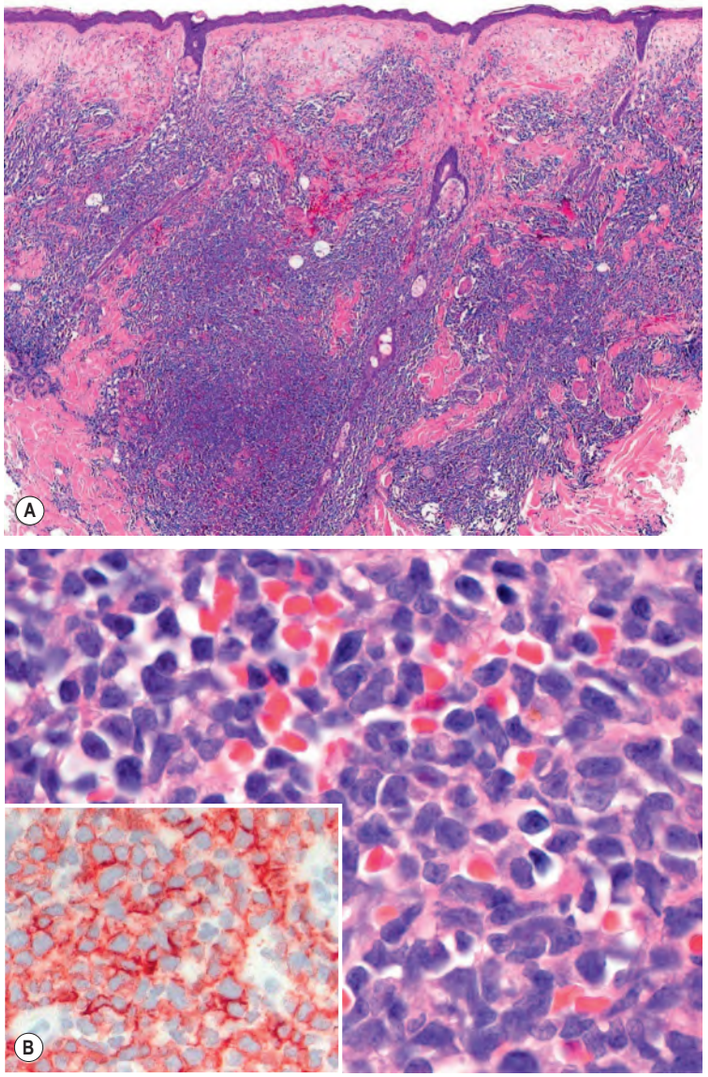

Fig. 121.11 Blastic plasmacytoid dendritic cell neoplasm. A Dense diffuse infiltrates of monomorphous blastoid cells within the entire dermis, with a grenz zone below the epidermis. **B** Diffuse infiltrate of medium-sized blastoid mononuclear cells admixed with extravasated erythrocytes; positive immunohistochemical staining for CD56 (inset). *Courtesy Lorenzo Cerroni, MD.*

blood, and bone marrow involvement in the majority of patients. Those individuals with initial negative staging eventually develop hematologic involvement. Symptoms of fevers, chills, night sweats, or weight loss are uncommon at presentation but may develop with disease progression.

Pathology

A diffuse dermal infiltrate of monotonous, atypical, medium-sized mononuclear cells is seen (Fig. 121.11A). These cells have fine blastic chromatin, indistinct nucleoli, and scant agranular eosinophilic cytoplasm. Intratumoral hemorrhage is common. In early lesions, the infiltrate may be perivascular and periadnexal. A grenz zone is almost always present and the infiltrate commonly extends into the subcutis[9,46,47].

Immunohistochemical studies are necessary to establish the diagnosis. The cells are CD4$^+$, CD56$^+$, CD123$^+$, TCL1$^+$, CD2AP$^+$, BDCA2$^+$/CD303$^+$, TCF4$^+$, myeloperoxidase$^-$, and EBV$^-$ (Fig. 121.11B). TdT is variably positive. Although there are descriptions of aberrant CD4$^-$, CD56$^-$, or CD123$^-$ cases, diagnostic immunophenotypic criteria have been established[9,28,29a,29b,46,48].

The tumor cells have germline configurations of Ig (H and L) and TCR genes, i.e. lack rearrangement. Abnormalities of several chromosomes, including regions that contain genes involved in cell cycle regulation, have been reported[43,49–51].

Differential diagnosis

The differential diagnosis includes AML and other cutaneous lymphomas. BPDCN, however, lacks IgH and TCR gene rearrangements and has a characteristic immunohistochemical profile (see above). There are subtypes of AML that may express CD4, CD56, and CD123, but expression of TCL1, BDCA2/CD303, TCF4, and CD2-associated protein (CD2AP) points to the diagnosis of BPDCN[9,52]. Of note, there are reports of patients with BPDCN developing AML[29a,29b,44].

Treatment

Initial treatment of BPDCN originally consisted of multidrug chemotherapeutic regimens. Although response rates were high (up to 80%), invariably patients relapsed followed by progression, with one year being the median overall survival. Currently, tagraxofusp (an anti-CD123 fusion protein composed of recombinant IL-3 fused to truncated diphtheria toxin) is the recommended first-line therapy for BPDCN. Depending upon duration of response, which is yet to be determined, it may serve as a bridge to allogeneic HSCT[53,54].

Angioimmunoblastic T Cell Lymphoma

Synonyms:
- Angioimmunoblastic lymphadenopathy
- Angioimmunoblastic lymphadenopathy with dysproteinemia

Key features

- Constitutional symptoms (fever, sweats, weight loss)
- Variable cutaneous manifestations, including morbilliform eruption, urticaria, and rarely, erythroderma
- Polyclonal gammopathy, autoantibodies, autoimmune hemolytic anemia, immune thrombocytopenia, and peripheral eosinophilia
- Generalized lymphadenopathy, hepatosplenomegaly, and pleural effusions
- Most commonly, a superficial perivascular infiltrate within the dermis with eosinophils, but not atypia of the lymphocytes

History

This disease was initially described in 1974 as angioimmunoblastic lymphadenopathy with dysproteinemia, and its features included generalized lymphadenopathy, hepatosplenomegaly, polyclonal hypergammaglobulinemia, and a hemolytic anemia[55,56].

Epidemiology

Angioimmunoblastic T cell lymphoma (AITL) is a relatively rare disease of the middle-aged and elderly, with a nearly equal incidence in men and women[56]. It represents the second most common subtype of peripheral T cell lymphoma (PTCL; see Ch. 120)[28,56].

Pathogenesis

AITL was originally considered to be an atypical reactive process or an abnormal immunologic reaction, until next-generation sequencing identified recurrent mutations in several genes (e.g. *DNMT3A*, *TET2*, *IDH2*, *RHOA*) within neoplastic T cells[57]. In addition, EBV is often present in non-neoplastic B cells[28,29], thus explaining the occasional development of B cell lymphomas in these patients. Currently, in the 5th edition of the WHO classification of hematolymphoid neoplasms and in the 2022 International Consensus Classification of mature lymphoid neoplasms, it is considered to be a subtype of follicular helper T-cell lymphoma[28,29].

Clinical features

Patients with AITL usually present at an advanced stage with fever, weight loss, night sweats, generalized lymphadenopathy, and hepatosplenomegaly[28,29,56,57]. Approximately one-half of the patients have cutaneous manifestations. The most common presentation is a widespread morbilliform eruption that resembles a viral exanthem. Other cutaneous findings include petechiae (often associated with thrombocytopenia), urticaria, purpura, papulonodules, and rarely, erythroderma[57–59]. EBV positivity has been reported to be more common in those with papulonodules as opposed to other cutaneous manifestations[59]. As with HD, generalized pruritus may be a presenting symptom[57].

Patients can develop a host of autoimmune diseases including rheumatoid arthritis, vasculitis, and the entities listed in key features. In addition hypergammaglobulinemia, multiple autoantibodies, and

Downloaded for Anonymous User (n/a) at Egyptian Knowledge Bank from ClinicalKey.com by Elsevier on March 10, 2024. For personal use only. No other uses without permission. Copyright ©2024. Elsevier Inc. All rights reserved.

peripheral eosinophilia, laboratory abnormalities include lymphopenia, elevated LDH, and cold agglutinins[28,29,55–57]. AITL has an aggressive behavior, with a median survival of <3 years[28,29,56,57]. Both circulating EBV DNA copy number and EBV positivity within skin lesions are considered negative prognostic markers[59].

Pathology

In the skin, the histopathologic features vary, with five patterns described to date. These include: (1) a superficial perivascular infiltrate composed of plasma cells, eosinophils, and lymphocytes that lack atypia (most common pattern); (2) a sparse perivascular infiltrate with atypical lymphocytes; (3) a dense superficial and deep infiltrate of pleomorphic lymphocytes; (4) a vasculitis, with or without atypical lymphocytes; and (5) necrotizing granulomas[28,29,56,57]. A presentation with necrotizing granulomas resembling an infectious process has been reported[58]. Similar to involved lymph nodes, the skin may have increased numbers of venules with a prominent endothelial lining ("high endothelial venules").

By immunohistochemistry, the neoplastic cellular phenotype corresponds to T follicular helper cells ($CD3^+$, $CD4^+$, $CD8^-$, $CD10^+$, PD-1^+, $ICOS^+$, Bcl-6^+, chemokine ligand $CXCL13^+$) plus clusters of $CD21^+$ follicular dendritic cells[60]. As noted previously, EBV-encoded RNA (EBER) is often detected within non-neoplastic B cells but not in the neoplastic T cells[29,59], and EBER-1^+ B cells more commonly accompany dense, superficial and deep infiltrates of pleomorphic, large-sized atypical lymphocytes[59].

Molecular analysis demonstrates a monoclonal TCR rearrangement and usually a polyclonal immunoglobulin pattern[29]. The most common chromosomal abnormalities are trisomy 3 and tristomy 5[61].

Differential diagnosis

The morbilliform nature of the eruption belies its malignant nature. Consequently, confusion with a drug eruption or viral exanthem is common. As cutaneous histologic changes are subtle, a specific diagnosis often cannot be rendered. Differentiation from other cutaneous lymphomas with a T follicular helper cell phenotype may be very difficult, and the diagnosis of cutaneous AITL can only be established in patients with proven extracutaneous AITL.

Treatment

The majority of patients present with stage III–IV disease[56,57] and treatment options include multidrug chemotherapeutic regimens (e.g. cyclophosphamide, doxorubicin, vincristine, and prednisone [CHOP]) versus CHOP plus brentuximab vedotin in those who have any evidence of CD30 expression in tumor cells. This may be followed by autologous HSCT. In patients with relapsed or refractory disease and a good performance status, allogeneic HSCT can be performed. Gentler palliative options include epigenetic modifiers such as histone deacetylase (HDAC) inhibitors (e.g. romidepsin) and possibly phosphoinositide-3-kinase inhibitors[56].

Lymphomatoid Granulomatosis

Key features

- EBV-driven angiocentric/destructive lymphoproliferative disorder
- Presents with cough, dyspnea, chest pain, and constitutional symptoms
- Cavitary pulmonary nodules on chest radiograph
- Nodular or ulcerative cutaneous lesions in 25%–50% of patients

History

Lymphomatoid granulomatosis (LG) was first described in 1972 as a pulmonary angiitis/granulomatosis that mimicked granulomatosis with polyangiitis. Initially thought to represent a reactive process, subsequent studies demonstrated a malignant clonal B cell population admixed with an abundant, polyclonal, reactive T cell population[28,29].

Epidemiology

LG is a rare disease of adults, usually presenting in the fifth to sixth decade of life. The male-to-female ratio is approximately 2:1. The disease can affect children, most commonly in the setting of immunodeficiency syndromes[28,29,62].

Pathogenesis

The pathogenesis of LG is often related to EBV infection, occasionally in combination with immunosuppression. Factors associated with LG include use of immunosuppressive medications (e.g. azathioprine, methotrexate, imatinib), HIV infection, Wiskott–Aldrich syndrome, X-linked lymphoproliferative syndrome, and additional lymphoproliferative disorders[28,29]. In the WHO classification of hematopoietic tumors, LG is categorized as an angiocentric/angiodestructive lymphoproliferative disease with variable histological grades[28,29].

Clinical features

Patients with LG present with symptoms related to pulmonary involvement, such as cough, dyspnea, and chest pain. Constitutional symptoms include fever, weight loss, malaise, arthralgias, and myalgias. Cutaneous lesions develop in 25%–50% of patients and usually present as nodules or ulcerated plaques (Fig. 121.12). Rarely, LG may present as a maculopapular exanthem. The kidney, brain, and gastrointestinal tract may be affected. In contrast to angioimmunoblastic T cell lymphoma, the lymph nodes and spleen are rarely involved.

Pathology

In LG, there are three histopathologic grades: (1) *grade 1* – polymorphous lymphoid infiltrate without cytologic atypia, along with a few large cells, and few cells are positive for EBV-encoded RNA 1 (EBER-1) and latent membrane protein via *in situ* hybridization and immunohistochemistry, respectively; (2) *grade 2* – polymorphous inflammatory background with scattered large cells and more abundant EBER-1^+ cells; and (3) *grade 3* – sheets of large B cells and numerous EBER-1^+ cells predominate over the inflammatory background. The amount of necrosis increases with the grade and angiocentricity/angiodestruction is consistently present. Granulomatous changes are often present. The neoplastic cells stain positively for CD20 and CD79a, and in most high-grade lesions there is a monoclonal rearrangement of the J_H genes[9,28,29].

Differential diagnosis

The clinical differential diagnosis includes various forms of cutaneous lymphoma, as well as infectious and inflammatory disorders (e.g. medium-sized vessel vasculitis, pyoderma gangrenosum). The histopathologic differential diagnosis is broad and encompasses most of the lymphoproliferative disorders mentioned above, including B cell and T cell lymphomas. Other disorders with histologic evidence of granulomatosis include granulomatosis with polyangiitis, sarcoidosis, and infectious processes. Diagnosis is based upon histopathologic findings plus immunohistochemical and molecular analyses. Because the existence

Fig. 121.12 Lymphomatoid granulomatosis. Ulcerated violaceous plaque in the popliteal fossa. *Courtesy Jean L. Bolognia, MD.*

Downloaded for Anonymous User (n/a) at Egyptian Knowledge Bank from ClinicalKey.com by Elsevier on March 10, 2024. For personal use only. No other uses without permission. Copyright ©2024. Elsevier Inc. All rights reserved.

of skin-limited disease without pulmonary involvement is debatable, such a diagnosis requires compelling evidence.

Treatment

LG follows an aggressive course, with the 5-year mortality ranging from 60% to 90%. For higher-grade disease, treatment commonly involves multidrug chemotherapy and/or rituximab (anti-CD20 monoclonal antibody), and, for grade 1 disease, IFN-α. Reversal of exogenous immunosuppression may also lead to clinical improvement[28,29].

Additional figures available in our eBook (see inside front cover for access code).

eFig. 121.1 Lymphocytic infiltrate of Jessner. Pink, arciform plaques on the mid back. On palpation, the lesions feel infiltrated. *Courtesy Lorenzo Cerroni, MD.*

eFig. 121.2 Lymphocytic infiltrate of Jessner. Pink plaques on the cheek composed of confluent papules. Note that one plaque is arciform. *Courtesy Lorenzo Cerroni, MD.*

eFig. 121.3 Lymphocytic infiltrate of Jessner. Infiltrated pink papules and plaques of the central back. Note the annular and arciform configuration (inset). *Courtesy Lorenzo Cerroni, MD.*

eFig. 121.4 Cutaneous lymphoid hyperplasia (lymphocytoma cutis). A Violet papulonodules on the helix and lobe of the ear (unknown etiology). **B** Multiple red–brown to violet papules at the sites of *Hirudo medicinalis* (medicinal leech) application. *B, Courtesy Josef Smolle, MD.*

Downloaded for Anonymous User (n/a) at Egyptian Knowledge Bank from ClinicalKey.com by Elsevier on March 10, 2024. For personal use only. No other uses without permission. Copyright ©2024. Elsevier Inc. All rights reserved.

eFig. 121.5 Cutaneous lymphoid hyperplasia (pseudolymphoma) – clinical presentations. A Pink nodule on and adjacent to the areola in an Austrian woman with *Borrelia burgdorferi*-associated lymphocytoma cutis. **B** Multiple red–brown to violet papules at the sites of *Hirudo medicinalis* (medicinal leech) application. *Courtesy Lorenzo Cerroni, MD*.

eFig. 121.6 Miliarial-type perifollicular B cell cutaneous lymphoid hyperplasia (pseudolymphoma). This is an unusual variant that presents as numerous violaceous perifollicular papules in the head and neck region. *Courtesy Karynne O. Duncan, MD*.

eFig. 121.7 Extramedullary hematopoiesis. "Blueberry muffin baby" secondary to congenital rubella. *Courtesy James Graham, MD*.

eFig. 121.8 Leukemia cutis. Multiple red–brown papules and plaques in a patient with hairy cell leukemia.

eFig. 121.9 Cutaneous Hodgkin lymphoma. Pink to red–brown papulonodules within a thin erythematous plaque; note the larger tumor on the hip. *Courtesy Lorenzo Cerroni, MD*.

Downloaded for Anonymous User (n/a) at Egyptian Knowledge Bank from ClinicalKey.com by Elsevier on March 10, 2024. For personal use only. No other uses without permission. Copyright ©2024. Elsevier Inc. All rights reserved.

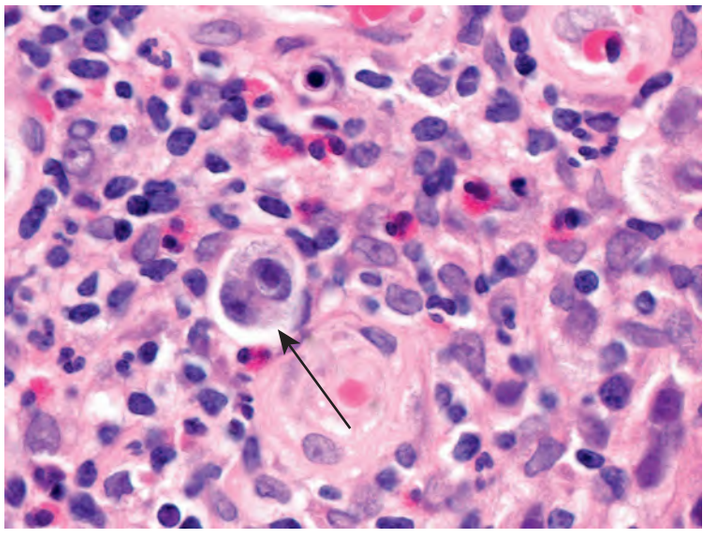

eFig. 121.10 Cutaneous Hodgkin lymphoma. Polymorphic infiltrate with lymphocytes, eosinophils, histiocytes, and a Reed–Sternberg cell (arrow). *Courtesy Lorenzo Cerroni, MD*.

eFig. 121.11 Cutaneous Hodgkin lymphoma. Large dull pink–brown plaque with central clearing is noted on the lower abdomen. The small ulceration represents the site of a previous skin biopsy.

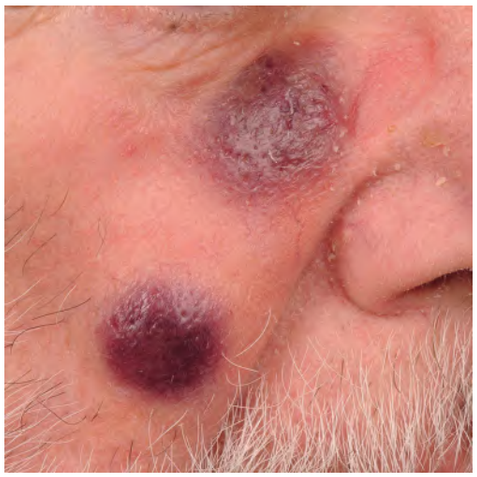

eFig. 121.12 Blastic plasmacytoid dendritic cell neoplasm. Two firm violaceous nodules on the cheek. *Courtesy Lorenzo Cerroni, MD*.

eFig. 121.13 Retiform purpura due to microvascular occlusion in a patient with advanced myelofibrosis. There are hemorrhagic bullae within the retiform purpura. *Courtesy Jonathan S. Leventhal, MD and Lauren Levy, MD*.

Downloaded for Anonymous User (n/a) at Egyptian Knowledge Bank from ClinicalKey.com by Elsevier on March 10, 2024. For personal use only. No other uses without permission. Copyright ©2024. Elsevier Inc. All rights reserved.